

A Case Study for Off-Loading

By **Andy Hoar**, *C Ped (C)*

Introduction

Ulcers occur in the diabetic neuropathic foot due to repetitive stress on insensitive feet. This repetitive stress causes the foot to develop hot spots, callus build-up, pressure necrosis, and ultimately ulceration. The most common area for pressure and excessive callus build-up occurs over the metatarsal heads, in particular the first metatarsal phalangeal joint (MTPJ) and the plantar surface of the Hallux¹. Effective reduction of pressure (off-loading) is considered essential in the healing of plantar ulcers². Useful off-loading mechanisms include reduction of walking speed, alteration of foot rollover during gait, and transfer of load from the affected areas to other areas of the foot or lower leg.

Although total contact casting (TCC) is considered to be the gold standard when off-loading neuropathic ulcers, it must be reapplied weekly and requires considerable experience on the part of the clinician to avoid creating new lesions. Some mechanisms used as alternatives to TTC are removable walking casts; custom neuropathic walkers, half shoes and the wound care shoe system (WCSS).

Key components of off-loading the forefoot during ambulation are the use of a rocker sole and relief of the local area of the ulceration. Peak pressures in the rocker-soled shoe are reduced by approximately 30% compared to a conventional shoe in the medial and central forefoot, but pressures are elevated in the heel and midfoot³. Local relief of the ulceration is accomplished by the removal of material from the supporting surface below the point of contact (ulceration).

Discussion

When assessing the neuropathic foot ulcer it is important to test the joint range of motion of the foot and ankle. The foot must have a dorsiflexion range of at least 10 deg. to allow ambulation without harm to the

Hallux⁴. Recognition of biomechanical issues such as Hallux Rigidus is key to successful off-loading. Without alteration of biomechanical stresses caused by bony or structural deformities, wound healing may be compromised and will likely be unsuccessful due to continued trauma.

The WCSS is versatile, requiring minimal equipments to modify. It offers the clinician off-loading mechanics in conjunction with standard best practice protocols, promoting optimal wound healing in areas without access to TCC. If TCC is contraindicated due to poor balance, infected wound or ischemia, then this is an acceptable alternative.

Case Vignette

Mr. H. is an active 29 year old. He has Type I diabetes, is a 1-ppd smoker, works full time at a warehouse, and plays softball on weekends.

Mr. H. was presented to the Leg Ulcer Clinic (LUC) with the development of callus over the first MTPJ and inter-digital joint (IPJ) of his left and right great toes. The multidisciplinary team consisting of a Vascular Surgeon, a Wound Care Nurse, a Vascular Technologist and a Pedorthist completed a detailed history and physical assessment. Part of this holistic assessment included an ankle brachial pressure index, Hgb A1C, Semmes Weinstein monofilament test and gait analysis.

The vascular lab reported an ankle brachial index of 1.15. A Semmes Weinstein monofilament test revealed loss of protective sensation to both feet. The range of motion of the first metatarsal phalangeal joint was evaluated by manual manipulation of the joint, which identified no movement in dorsiflexion, and this is known as Hallux Rigidus. Gait analysis identified altered mechanics of the foot during the stance and propulsion phases of gait, resulting in localized repetitive pressure upon the Hallux. The shoe wear pattern was consistent with Hallux Rigidus.

Treatment Plan

Pressure off-loading with a pressure reduction footwear system, debridement of callus, standard wound care best practices and enrolment in a Vascular Risk Reduction Program.



fig #1



fig #2

Mr. H. was fitted with a WCSS (*fig#1*). Proper fitting included total width and length, velcro strap closure length and placement of apex of the rocker sole. To ensure optimal effect of the rocker sole the apex must be located proximal to the metatarsal heads 5. The plantar contact system enables the practitioner to off-load plantar ulcerations with four layers (multiple durometer) of material 6. The top layer of the four-layer system to contact the foot is always a solid interface (plastizote®) that will mold to the foot contours. There are two layers of higher density ethel vinyl acetate (EVA) that is relieved using scissors and a small grinder to smooth the edges. The location of the relief is transferred to the top layer by demarcating the ulcer with a jel ink pen and having the patient stand wearing the WCSS. The ink is transferred to the top layer. The centre of the ulcer is then determined. A relief larger than the ulcer is cut out of each of the lower layers directly under the ulcer .5cm wider medially, laterally, proximally and 1.25 cm wider distally. It is important to skive the edges (approx. 30 degrees) so that the relief away from the foot is slightly larger than the relief on the upper surface (*fig#2*)

Mr. H. was informed of the purpose and proper use of the WCSS. Great emphasis was placed on the importance of wearing the WCSS when weight bearing and limiting ambulation to self-care. Follow-up appointments were scheduled every 2 weeks where the fit, function and wear pattern of the WCSS was evaluated. Adjustments such as the replacement of top plastizote layer due to compression of the material were then completed,

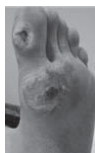

fig #3

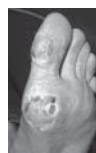

fig #4

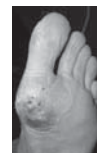

fig #5

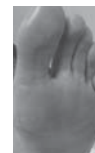


fig #6

Initial visit (*fig#3*) the callus and necrotic tissue were debrided exposing category 4a plantar ulcerations of the left first MTPJ measuring 1cm by 1cm. and the IPJ of the Hallux measuring .5cm by .5cm.

By week four (*fig #4*) the MTPJ wound had reduced measuring .5cm x. 5cm. The wound at the IPJ of the Hallux had closed and developed minimal callus.

By week six (*fig#5*) the MTPJ wound had reduced measuring .2cm by .3cm. The Hallux callus remained minimal. The staining in the area of the MTPJ is residual Cadexomer Iodine.

By week eight (*fig#6*) the wounds have closed and callus development was minimal.

Results

Mr. H. has progressed to wearing custom foot orthotics and modified athletic footwear. The orthotics incorporate a 5mm accommodation at the first metatarsal joint on the right and 7.5mm on the left, metatarsal pads and full-length poron/plastizote covers. Footwear was selected to provide a deep wide toe box and has been modified to include a 12mm rocker sole bilaterally.

He has stopped smoking, returned to work, and with the assistance of his employer changed jobs to a clerical position requiring less ambulation. Sadly, he no longer plays softball. Mr. H. still wears the WCSS as a house shoe every day and avoids walking in bare feet. Mr H. continues to be screened every 3 months, at which time the orthotic plastizote cover is replaced due to compression and the footwear condition is evaluated.

Hoar A. A case study for off-loading. *Wound Care Canada*. 2008;6(1):58-59.

Reprinted with permission of the Canadian Association of Wound Care (CAWC).

Wound Care Canada is the official publication of the CAWC.